

Photorefractive keratectomy with an ablatable mask and rail system for simultaneous correction of myopia and astigmatism: preliminary results

Gregory J. Culp,* BSc; Bonnie I. Culp,* RN;
Jack T. Holladay,† MD; Patricia K. Teal,* MD

ABSTRACT • RÉSUMÉ

Background: Alternative methods to correct myopic astigmatism with excimer laser surgery are being examined in an attempt to increase efficacy and reliability. One approach that is developing interest is the incorporation of a polymethylmethacrylate mask into the laser procedure. We examined the efficacy and safety of the Summit Apex Plus laser using a new ablatable mask and rail system.

Methods: Retrospective study based on follow-up of patients at 1 month (59 eyes), 3 months (37 eyes) and 6 months (24 eyes) at an eye laser centre in southern Ontario. Patients were recruited from 19 ophthalmic practices located primarily in the Niagara region and in western New York. Selected patients with naturally occurring myopia and astigmatism were treated with the Summit Apex Plus laser with the mask and rail system. Patients were evaluated for changes in refraction and visual acuity, and complications (including glare, haloes, haze and lines lost of best corrected visual acuity) were assessed. We calculated the surgically induced refractive change using the Holladay 10-step method.

Results: At 6 months the average residual sphere for the low myopia group (-7.00 dioptres or less) was -0.60 D and for the high myopia group (greater than -7.00 D) -0.61 D. This result was found to be both stable and accurate over the follow-up period. The cylinder component was reduced irrespective of the amount of preoperative myopia. Vector analysis showed that in most patients the correction of astigmatism was accurate, although slight undercorrection was observed. Complications were minimal, with few residual adverse effects at 6 months.

Interpretation: We found the mask and rail technique to be both effective and safe. Refractive change was stable and accurate, although astigmatism was slightly undercorrected. The procedure resulted in few complications, most of which resolved by 6 months.

Contexte : Dans le but d'augmenter l'efficacité et la fiabilité de la chirurgie au laser pour la correction de l'astigmatisme myopique, on étudie de nouvelles méthodes opératoires. L'incorporation à l'opération d'un masque en polyméthylméthacrylate

From *the Eye Laser Centre, Fort Erie Medical Centre, Fort Erie, Ont., and †the Hermann Eye Center, Houston, Tex.

Reprint requests to: Dr. Patricia K. Teal, Eye Laser Centre, Fort Erie Medical Centre, 238 Bertie St., Fort Erie ON L2A 1Z3

Accepted for publication Sept. 21, 1998

Can J Ophthalmol 1999;34:9-16

est l'une de celles qui suscitent le plus d'intérêt. Nous avons évalué l'efficacité et la sécurité du laser Summit Apex Plus lorsqu'il est combiné à un nouveau système de masque et de rail pour l'ablation.

Méthodes : Étude rétrospective reposant sur le suivi de patients un mois (59 yeux), trois mois (37 yeux) et six mois (24 yeux) après l'opération à un centre de chirurgie oculaire au laser du sud de l'Ontario. Les sujets ont été choisis dans 19 centres de soins ophtalmiques situés principalement dans la région du Niagara et dans l'ouest de New York. Il s'agissait de personnes dont la myopie était survenue naturellement. Les patients choisis ont été traités au moyen du laser Summit Apex Plus avec le système de masque et rail. Nous avons évalué les changements sur les plans de la réfraction et de l'acuité visuelle, de même que les complications (éblouissement, halos, vue brouillée et pertes de lignes au niveau de la meilleure acuité visuelle corrigée). Nous avons calculé le changement au niveau de la réfraction provoqué chirurgicalement en utilisant la méthode Holladay en dix étapes.

Résultats : Au bout de six mois, la sphère résiduelle moyenne pour le groupe à myopie faible ($-7,00$ dioptries ou moins) était de $-0,60$ D et pour le groupe à myopie forte (supérieure à $-7,00$ D), de $-0,61$ D. Ce résultat a été jugé à la fois stable et exact pendant la période de suivi. L'élément cylindrique a été réduit indépendamment du degré de myopie avant l'opération. L'analyse vectorielle a montré que chez la plupart des patients, la correction de l'astigmatisme était exacte, bien qu'une légère sous-correction soit observée. Les complications ont été minimales, et il y a eu peu d'effets secondaires résiduels au bout de six mois.

Interprétation : Nous avons trouvé que la technique masque et rail était à la fois efficace et sûre. Le changement au niveau de la réfraction était stable et exact, bien que l'astigmatisme soit légèrement sous-corrigé. L'intervention a entraîné peu de complications, dont la plupart ont été résolues au bout de six mois.

Excimer laser surgery has quickly become one of the most common surgical procedures in North America. In its earliest application, nearly a decade ago, the technique was found to be relatively safe and effective for the correction of low myopia. Further advancements in laser technology have improved the reliability and safety of the procedure.¹⁻⁵ Success in the treatment of low myopia has raised interest in correcting more complex forms of refractive error, including hyperopia and astigmatism.

One area that has gained attention is the correction of compound myopia and astigmatism. To date, most reports have centred on the use of aperture elements and scanning techniques to correct this form of refractive error. These techniques have been relatively successful, with the best results in patients with low amounts of preoperative myopia.⁶⁻¹⁶

Alternative methods to correct compound astigmatism are being examined in an attempt to increase efficacy and reliability. One approach that is developing interest is the incorporation of a polymethylmethacrylate (PMMA) mask into the laser procedure. In practice, such a mask can be used as a substrate in the path-

way of the laser in order to transfer a desired ablation pattern onto the cornea. Previous studies examining this technique have given promising results.¹⁷⁻¹⁹ We carried out a study to examine the efficacy and safety of the Summit Apex Plus excimer laser (Summit Technology Inc., Waltham, Mass.) using a new mask and rail system.

METHODS

In the Summit mask and rail system there are 10 different PMMA mask types, from which the full range of myopic and astigmatic correction can be achieved. The PMMA disc itself is held within a cassette for support and also for alignment along the desired axis of astigmatism. The cassette can be inserted and removed from the laser system quickly and effortlessly via the rail apparatus (Fig. 1). This is superior to the previous handheld techniques as there is less chance for misalignment. Furthermore, the desired axis of astigmatism can easily be set on the cassette. After the desired correction is programmed into the computer, the laser ablates the PMMA disc.

Selective ablation of the disc in turn patterns the ablation onto the cornea, with the effect of expanding the beam and, hence, achieving a smoother corneal surface. Using the mask as a template allows myopia and astigmatism to be corrected simultaneously. The ablation makes use of a central optical zone of 100% correction and an outer blend zone of decreasing power (Fig. 2). This gradual transition decreases the amount of tissue removed and also produces a smooth corneal surface. The latter is important to decrease epithelial hyperplasia, haze and regression of the surgically induced refractive change, which can follow surgery.

We have been using the toric mask and rail procedure at our centre for 1 year. The surgery was made available to patients under standard indications. Specifically, patients with naturally occurring myopia and astigmatism with a stable refractive history were considered eligible for the procedure. Previous corneal surgery or a history of ocular or systemic disease known to affect surgical outcome was a contraindication. All surgery was performed at the Eye Laser Centre, Fort Erie, Ont., by one of two physicians (one of whom was P.K.T.). Patients were referred

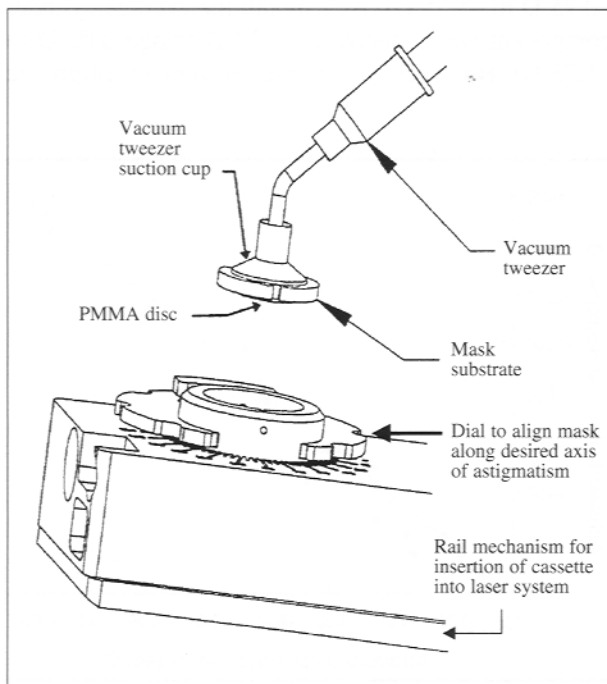


Fig. 1—Diagram of the Summit cassette mechanism and polymethylmethacrylate (PMMA) disc. Sidebars on the cassette allow the cassette to be inserted into the laser mechanism via a set of rails. The disc is inserted into the cassette via a vacuum tweezer-suction cup mechanism (courtesy Summit Technology Inc., Waltham, Mass.).

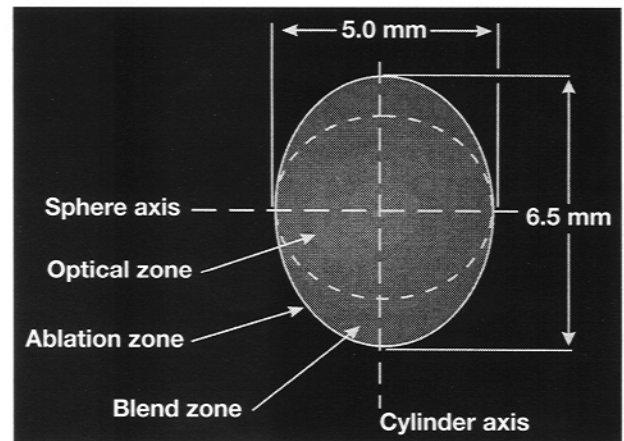


Fig. 2—Diagram of toric ablation technique. The zone of optical correction is shown in which the spherocylindrical ablation takes place along the sphere and cylinder axes. Also shown is the outer ablation zone (the outer boundary of ablation). The intermediary blend zone allows a smooth, gradual transition between the zone of correction and outer ablation zone (courtesy Summit Technology Inc.).

from 19 centres located primarily in the Niagara region of Ontario and in western New York.

Before surgery, anesthetic (4% lidocaine) and non-steroidal anti-inflammatory (ketorolac tromethamine) were administered topically. The PMMA mask was aligned in the cassette according to the axis of minus cylinder. The Summit 193-nm argon-fluoride Apex Plus excimer laser was used in all cases. The vertex distance and the patient's cycloplegic refraction were programmed into the computer, and the ablation profile was calculated automatically by algorithm. For consistency, our centre expresses astigmatism in the negative cylinder format. An optical zone of 5.0 mm with full correction and a 6.5-mm blend zone were standard for all patients. Before surgery, a sterile lid speculum was placed in the operative eye. The patient fixed on a green diode light to aid in alignment. Simultaneously, the physician used helium-neon beams focused at 3 and 9 o'clock on the pupillary margin and aligned with the 180° axis on the peripheral cornea. The epithelium was removed with a #69 Beaver blade (Alcon Canada Inc., Mississauga, Ont.) before ablation. Characteristics of the ablation profile included a repetition rate of 10 Hz and a fluency of 180 mJ/cm².

Following treatment, a bandage contact lens was placed on the treated eye and left in place for 3 days. Therapy was started with 0.5% ketorolac and tobramycin-dexamethasone to control pain and

infection. Once the contact lens was removed, the patient was prescribed 0.25% fluorometholone drops, instilled three times per day for 1 month then gradually tapered.

Follow-up was performed at 1, 3 and 6 months post-operatively. At each visit, changes in refraction and visual acuity were recorded. Any complications that might have developed were also assessed. Haze was recorded on a scale of 0 (clear) to 5 (most severe). Haze graded as 3 or more was considered an adverse reaction.

Patient data were entered into a database to be grouped and analysed. To address results based on the amount of preoperative myopia, patients were classified as high myopes (greater than -7.00 dioptres) or low myopes (-7.00 D or less). To assess changes in astigmatism, patients were categorized as having low (-1.50 D or less), moderate (-1.75 D to -3.00 D) or high (greater than -3.00 D) preoperative cylinder values. The preoperative average values for the patients followed at 1, 3 and 6 months were used to analyse trends in average refractive change at 1, 3 and 6 months respectively. We performed vector analysis using the Holladay method²⁰ to assess the surgically induced refractive change. This in turn was used to assess the accuracy of surgical correction.

RESULTS

We had data for 59 eyes at 1 month, 37 eyes at 3 months, and 24 eyes at 6 months. The age of the patients ranged from 23 to 66 years. There were equal numbers of men and women.

Sphere

The average sphere preoperatively for the eyes followed at 1 month in the low myope group was -3.88 D (range -0.50 D to -7.00 D). The corresponding value for the high myope group was -9.33 D (range -7.25 D to -15.00 D). For both groups the average spherical value approached emmetropia at 1 month (Table 1). This remained relatively stable throughout the follow-up period. Average values at 1, 3 and 6 months remained quite close to the goal of complete correction. However, there was a subtle trend of myopic regression in both the high myopia and low myopia groups. Interestingly, there was no difference in the amount of regression between the two groups.

In most patients the spherical change was quite close to the intended value (Fig. 3). This accuracy

Table 1—Change in mean sphere at 1, 3 and 6 months for patients undergoing excimer laser correction of myopic astigmatism with an ablatable mask and rail system

Time since surgery	Group; mean sphere, D			
	Low myopia (≤ -7.00 D)		High myopia (> -7.00 D)	
	Before surgery	After surgery	Before surgery	After surgery
1 mo	-3.88 (n = 46)	-0.07	-9.33 (n = 19)	-0.24
3 mo	-4.03 (n = 30)	-0.24	-8.95 (n = 11)	-0.45
6 mo	-4.47 (n = 17)	-0.60	-7.86 (n = 17)	-0.61

seemed to endure irrespective of the amount of preoperative myopia.

Correction of cylinder

Overall, the cylinder correction obtained was satisfactory. The preoperative average cylinder for the patients followed at 1 month was -2.02 D (range -0.75 D to -5.75 D). At 1 month the average cylinder component was reduced to -0.29 D (range 0.00 D to -1.75 D). However, to gain a clear view of astigmatic

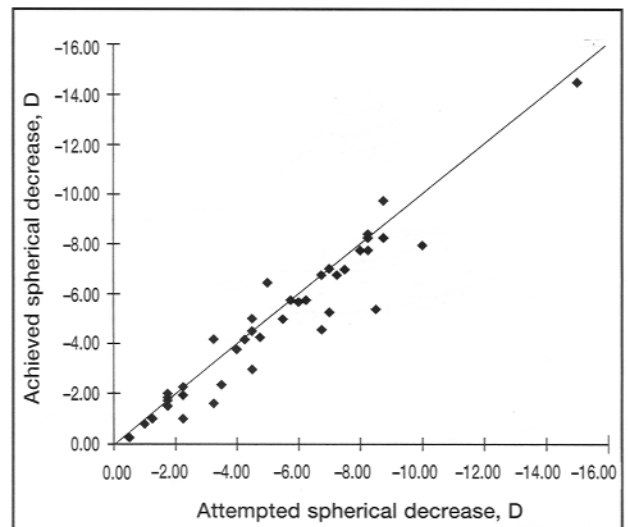


Fig. 3—Scattergram of attempted versus achieved spherical change at 3 months for the 41 patients followed at 3 months. The oblique line represents exact correlation between attempted and achieved correction, and values above and below the line indicate overcorrection and undercorrection respectively.

Table 2—Correction of cylinder as a function of preoperative myopia

Time since surgery	Group; mean cylinder, D			
	Low myopia		High myopia	
	Before surgery	After surgery	Before surgery	After surgery
1 mo	-2.07	-0.35	-1.92	-0.17
3 mo	-2.02	-0.53	-1.77	-0.30
6 mo	-1.88	-0.47	-1.89	-0.39

treatment, it is instructive to examine the results as a function of the magnitude of preoperative sphere and cylinder. Table 2 shows the correction of cylinder as a function of preoperative myopia. Although the average preoperative cylinder was somewhat larger for the low myopia group than the high myopia group, the two groups obtained a similar degree of correction, which remained stable throughout the follow-up period.

The effect of preoperative astigmatism on the correction of cylinder is shown in Table 3. The average postoperative cylinder was reduced to approximately the same value irrespective of the amount of preoperative astigmatism.

It was evident that some degree of cylinder undercorrection was being encountered. To examine this on an individual basis, we constructed a scattergram to determine the magnitude of cylinder change at 3 months (Fig. 4). Although some patients had complete correction of the cylinder component, undercorrection was a prevalent finding. Fig. 4 also suggests that patients with small amounts of preoperative cylinder experienced relatively more undercorrection than patients with large amounts of preoperative cylinder, as evidenced by the proximity to the oblique line. The patients with low cylinder preoperatively had an aver-

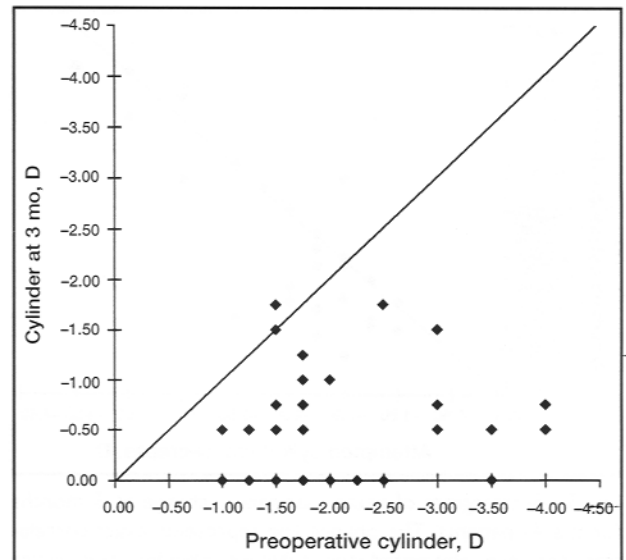


Fig. 4—Scattergram of net preoperative versus postoperative cylinder values at 3 months for the 41 patients. The oblique line represents no net change in cylinder magnitude, and values above and below the line indicate net overcorrection and net undercorrection respectively.

age correction of 72%, the patients with moderate cylinder preoperatively had an average correction of 78%, and the patients with high cylinder preoperatively had an average correction of 86%. One patient experienced a net change of 0.00 D (which was later reduced with healing at 6 months), and one patient had a larger cylinder value postoperatively. The latter patient experienced a 46° shift in axis, which may have been induced surgically or by an adverse healing reaction.

We calculated the surgically induced refractive change to examine the actual correction of cylinder achieved during surgery. This procedure incorporates

Table 3—Correction of cylinder based on preoperative astigmatism

Group	Time; mean value, D			
	1 mo		3 mo	
	Preoperative astigmatism	Postoperative cylinder	Preoperative astigmatism	Postoperative cylinder
Low cylinder (≤ -1.50 D)	-1.25 (n = 21)	-0.40	-1.30 (n = 14)	-0.43
Moderate cylinder (-1.75 D to -3.00 D)	-2.18 (n = 29)	-0.61	-2.09 (n = 20)	-0.46
High cylinder (> -3.00 D)	-3.03 (n = 8)	-0.34	-3.60 (n = 5)	-0.50

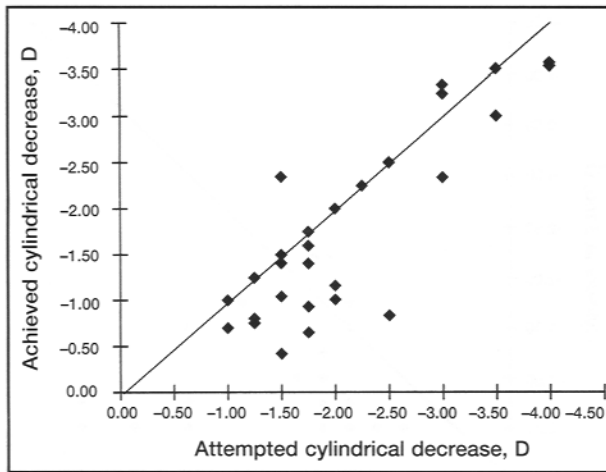


Fig. 5—Scattergram of vector astigmatic change at 3 months for the 41 patients. The oblique line represents exact correlation between attempted and achieved cylinder, and values above and below the line indicate overcorrection and undercorrection respectively.

the cylinder and axis as a vector (as opposed to a simple magnitude) and therefore gives the true value of cylinder change. The result of this analysis at 3 months is shown in Fig. 5. In most patients the correction of cylinder was quite accurate; however, a minority of patients experienced slight undercorrection. Undercorrection was the most common finding. Again, this was most evident in patients with a low to moderate amount of preoperative astigmatism.

Information about the accuracy of astigmatic correction can be gained by looking at the net change in axis. Fig. 6 summarizes the magnitude of axis deviation between pre- and postoperative values. At 1 month and 3 months most patients (about 70%) with remaining cylinder were within 0° to 10° of their ini-

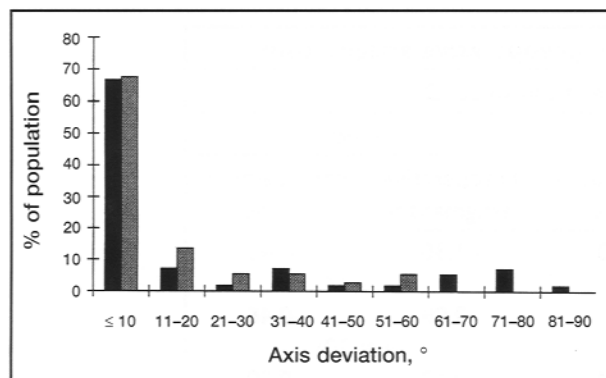


Fig. 6—Net change in axis of astigmatism at 1 month (59 eyes) (black bars) and 3 months (41 eyes) (grey bars).

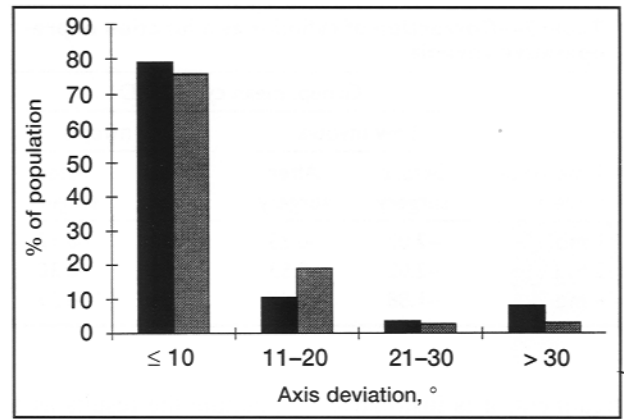


Fig. 7—Effective axis deviation at 1 month (59 eyes) (black bars) and 3 months (41 eyes) (grey bars).

tial axis, and nearly all patients were within 20°. Axis deviation was more accurate at 3 months than at 1 month, perhaps because of transient deviations caused by the healing reaction still occurring at 1 month. At 1 month one patient had an axis deviation of 80° to 90°, which indicated overcorrection. This patient had a preoperative cylinder of -1.75 D at 150° but was actually corrected at -2.25 D at 150°, leaving a cylinder of -0.50 D at 62° (or +0.50 D at 150°). Three-month results for this patient are not yet available; at the time of writing, the patient had a visual acuity of 20/30.

Nearly 80% of the patients were within 10° of the intended correction (surgically induced refractive change), and almost 100% were within 20° of intended correction (Fig. 7). This result indicates a high degree of accuracy during ablation of the desired cylinder during surgery. Thus, although the cylinder component was undercorrected in several patients, this was not due to a deviation from the intended axis but, rather, to simple undercorrection in cylinder magnitude.

Complications

At 1 month minor amounts of haze were not uncommon, particularly in patients with higher amounts of preoperative myopia. However, only three patients in the group with follow-up at 3 months had clinically significant haze (all had a haze score of 3). These minor problems continued to recede at 3 months. At 6 months only one patient exhibited clinically significant haze, a finding uncorrelated with preoperative myopia (the preoperative sphere was -1.75 D). The patient's visual acuity at 6 months was 20/30. One patient was recorded to have lost 1

line of visual acuity; however, this appears to have been due to an unrelated problem (the formation of ectropion).

Visual acuity

At 6 months 88% of the patients in the low myopia group had 20/40 or better vision, and 24% had 20/20 vision. Surprisingly, the high myopia group had similar results (86% and 29% respectively).

INTERPRETATION

We found the Summit mask and rail system to be very efficient and easy to use. Specifically, we found that the addition of the cassette and rail resulted in a large decrease in surgical time and technical difficulty. This is a substantial improvement over earlier techniques that made use of the mask.¹⁸

The efficiency of the laser in correcting compound myopia and astigmatism was quite satisfactory. Correction of the spherical component was both predictable and highly stable. Interestingly, there was no obvious difference between the low myopia and high myopia groups in either of these categories. Most researchers have found correction of high myopia alone to be associated with regression and relatively poor predictability.²¹⁻²⁵ The relatively high degree of stability in our patients with high myopia may be due to the smooth ablation surface that is characteristic of this system. Further follow-up is needed to determine the longevity of these findings.

We found the correction of the cylinder component to be satisfactory as well, although not as dramatic as that observed for the sphere. The value of the cylinder was reduced to an average of approximately -0.50 D irrespective of the amount of preoperative cylinder. Thus, although most of the cylinder component was corrected, many patients were left with a small amount of residual astigmatism. This is not an uncommon result in toric photorefractive keratectomy.^{7,9,10,13} We feel that this result is most likely explained by one of two reasons. The first possibility is that the magnitude of the surgical correction may have been insufficient to produce total correction. Alternatively, there may have been a deviation between the axis of astigmatism and the actual axis of ablation. Both scenarios would result in incomplete correction of the preoperative cylinder. Our findings suggest that the first explanation is more likely. Most of the patients had a postoperative axis close to the preoperative value.

Furthermore, vector analysis showed that almost all of the patients had a surgical ablation within 20° of the intended axis. Thus, we may conclude that the cylindrical ablation in most patients was quite accurate (i.e., in axis) but insufficient in magnitude. This can be easily remedied by a change in the computer algorithm that directs the ablation.

Our results suggest that correction of the cylinder was not affected by the degree of preoperative myopia. Tabin and colleagues¹³ reported an increase in the occurrence and magnitude of unintentionally induced astigmatism in patients with higher degrees of preoperative myopia. They postulated that this finding was a product of the healing reaction. If this is true, our results may indicate that the smooth ablation pattern produced with this system may not lead to this form of adverse healing response. Further follow-up and a larger population of patients is necessary to examine this possibility.

We feel that with further healing past 6 months the visual acuity scores of our patients will continue to improve. Furthermore, as patients become accustomed to the spherocylindrical change in their prescription, their overall visual acuity should benefit.

In conclusion, we found the mask and rail technique to be a highly satisfactory method to correct compound myopia and astigmatism. High degrees of preoperative myopia seem to be particularly amenable to this procedure. Further follow-up is needed before any definitive conclusions can be made in this regard. We also found that correction of the cylinder was both accurate and predictable, although many patients were left with a small amount of residual astigmatism. Complications were minimal, with haze being the most frequently encountered finding; however, most problems had resolved by 3 to 6 months.

This work was supported by a grant from Physicians Services Incorporated, Toronto.

REFERENCES

1. Gartry DS, Kerr Muir MG, Marshall J. Excimer laser photorefractive keratectomy; 18-month follow-up. *Ophthalmology* 1992;99:1209-19.
2. Brancato R, Tavola A, Carones F, Scialdone A, Gallus G, Garancini P, et al. Excimer laser photorefractive keratectomy for myopia: results in 1165 eyes. *Refract Corneal Surg* 1993;9:95-104.
3. Salz JJ, Maguen E, Nesburn AB, Warren C, Macy JJ, Hofbauer JD, et al. A two-year experience with excimer laser photorefractive keratectomy for myopia. *Ophthalmology* 1993;100:873-82.